'Atiqot 103, 2021

Crusader- and Ottoman-Period Faunal Remains from the *Boverel* Quarter, 'Akko

Guy Bar-Oz

Introduction

The excavation of the building in the Old City of 'Akko produced a small faunal assemblage found within a Crusader-period context (late thirteenth century CE; see Stern, this volume). The fact that the house was destroyed and never rebuilt provides a snapshot of the culinary behavior and meat-eating habits of its residents. In addition, the presence of several identified bones from an overlying Ottoman-period deposit permits comparisons between the eating habits of both periods.

All the faunal material was hand-picked through the excavated deposits. Zooarchaeological data were collected following the procedures outlined in Raban-Gerstel, Bar-Oz and Tepper (2011). Taxonomic identifications were made using the comparative collection of the Laboratory of Archaeozoology, University of Haifa. Skeletal modifications of specimens were inspected macroscopically using a low-resolution magnifying lens (× 2.5) to detect butchery marks or any other anthropogenic bone-surface modification. Aging data were collected based on epiphyseal fusion of long bones, and dental eruption and wear of mandibular teeth.

The Assemblage

The assemblage is small and heavily fragmented, composed mainly of bone fragments of livestock taxa. The distribution of the identified and non-identified bone remains are detailed according to locus and basket in Table 1. Distribution of animal bones from Ottoman-period Stratum II (L16) and Crusader-period Stratum III (all other loci) is given in Table 2 and in Fig. 1. The Crusader deposits yielded 67 faunal specimens that were identified to skeletal element. The Ottoman stratum comprises 18 identified skeletal elements.

The majority of the bones in both strata belong to sheep, goat and cattle. Significantly, pig remains are present only in the Crusader deposits. Other species represented by single specimens are domestic fowl. In addition, isolated remains of cat bones, two vertebras of fish and a single equid bone were noted. The presence of pigs in the Crusader-period deposits could attest that the house was inhabited by Christian residents.

Table 1. Distribution of Identified Bone Remains, according to Locus and Basket

Locus	Basket	Total Weight	Unidenified Weight	No. of Identified Bones
12	105	134	102	4
12	106	123	70	4
12	109	317	52	11
13	114	166	84	4
15	117	398	285	19
16	120	157	53	3
16	121	278	123	7
16	122	81	46	6
16	123	294	177	6
16	124	45	45	2
17	125	25		1
17	126	25	6	1
17	128	208	129	17
				85

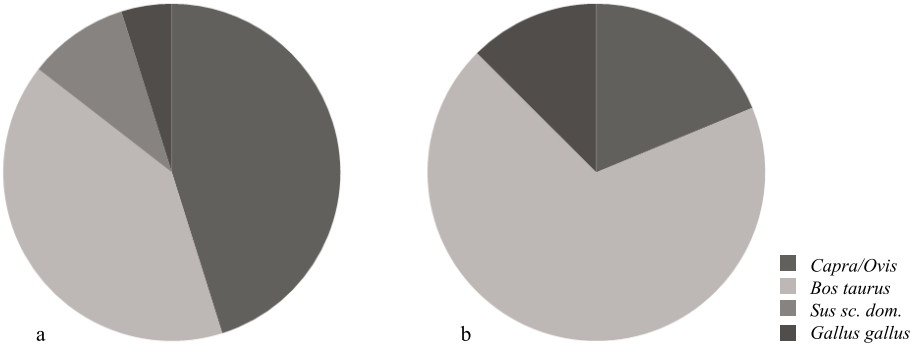

Fig. 1. Distribution of Animal Taxa in the Crusader (a) and Ottoman (b) Deposits.

Based on taxonomically distinctive features, both sheep (*Ovis aries*) and goat (*Capra hircus*) are represented, but their taxonomic separation was not inclusive. The small bone sample from this excavation precludes comprehensive reconstruction of the livestock demographic profile. Nevertheless, it seems that sheep, goat and cattle remains are overrepresented by adult individuals in both periods. Only one proximal femur and a single calcaneus of sheep/goat from the Crusader period, and another proximal femur from the Ottoman period, were unfused, while the rest of the assemblage comprised fully-fused long bones. Similarly, deciduous teeth are completely lacking for sheep and goat, and include only a single cattle specimen from the Crusader deposits. The low juvenile ratio of sheep and

Table 2. Number of Identified Specimen (NISP) and Minimum Number of Individuals (MNI) of Each Taxon in the Crusader and Ottoman deposits

	Capra hircus/Ovis ones		*Bos taurus*		*Equus* sp.		*Sus* sc. dom.		*Gallus gallus*		*Catus* sp.		Fishes	
	Crusader	Ottoman	Crusader	Ottoman	Crusader	Ottoman	Crusader	Ottoman	Crusader	Ottoman	Crusader	Ottoman	Crusader	Ottoman
Head														
Mandibular ramus	1													
Mandibular Teeth	4		2											
Maxillar Teeth			4	1										
Body														
Rib	7		5	3			1							
Scacrum			1											
Cervical Vertebrae	2			1										
Forcula									1					
Lumbar Vertebrae	1												1	1
Forelimb														
Scapula Glenoid Fossa												1		
Humerus complete							1				1			
Radius proximal	1		1				1							
Radius complete														
Ulna proximal			2											
Metacarpus proximal				1										
Metacarpus complete	2		1	1										

Table 2. (cont.)

	Capra hircus/Ovis ones		*Bos taurus*		*Equus* sp.		*Sus* sc. dom.		*Gallus gallus*		*Catus* sp.		Fishes	
	Crusader	Ottoman	Crusader	Ottoman	Crusader	Ottoman	Crusader	Ottoman	Crusader	Ottoman	Crusader	Ottoman	Crusader	Ottoman
Hind Limb														
Pelvic Acetabulum	5													
Femur complete									1	2				
Femur proximal	1			1			1							
Tibia complete														
Tibia proximal		3							1		1			
Astragalus			1		1									
Cntral 4th			1											
Calcaneus	1													
Metapod			3				1				1			
Metatarsus proximal	1		1											
Toes														
Phalanx 1	2		1	3			1							
Phalanx 3			2											
NISP	28	3	25	11	1	0	6	0	3	2	3	1	1	1
%NISP	42%	17%	37%	61%	1%		9%		4%	11%	4%	6%	1%	6%
MNI	2	2	2	1	1	0	1	0	2	0	1	0	1	0

goat and cattle indicate that animals were slaughtered only after they had reached maturity. By contrast, the majority of Crusader pig remains originate from young individuals (three out of six long bones were unfused). This suggests that pigs were butchered at their optimal age for meat consumption.

The Crusader-period bone assemblage is too small to allow for a detailed analysis of anatomical representation. Yet, it appears that the occurrence of sheep and goat, and cattle skeletal elements from all body parts, represents a mixture of both domestic and butchery refuse, as there is no discrepancy between meaty (upper long bones) or less meaty elements (skull, lower limbs and hoof).

Butchery marks and remains of carnivore ravaging on bones provide some further information on the depositional history of the assemblage. The butchery marks include two dismemberment marks (ulna and astragalus), and one chopped rib on Crusader-period cattle remains. Another chopped rib was noted in the Ottoman-period cattle remains. Interestingly, burned bones are completely absent.

Additional bone surface modifications are traces of carnivore puncture tooth-mark and chewing, all of which most probably relate to ravaging dog activities. Those marks were found on both Crusader- and Ottoman-period bones: two specimens from the Crusader period (proximal metacarpus of cattle and metatarsus complete of sheep/goat), and four specimens from the Ottoman period (three proximaltibia and a proximal rib of cattle). This may indicate the attractiveness of fresh flesh to stray dogs after the house was destroyed.

Conclusions

The Crusader- and Ottoman-period faunal assemblage from this excavation in ʻAkko is small but significant, given its special context. The faunal remains clearly demonstrate the shift in the culinary habits that occurred with the replacement of cultural entities in ʻAkko. While pork was consumed more frequently in the Crusader period, when the town was under Christian rule, it is strictly absent from later Ottoman deposits. It is the pig again that pinpoints the diversity of ʻAkko's inhabitants, and the shift that occurred in the cultural identity of its residents.

References

Raban-Gerstel N., Bar-Oz G. and Tepper Y. 2011. The Bone and Horn Industry in Late Ottoman Nazareth: The Evidence from Shihab ad-Din. *ʻAtiqot* 67:61–80.

Stern E.J. This volume. The Last Years of Crusader Acre (ʻAkko) and Resettlement in the Ottoman Period: Archaeological Evidence from the *Boverel* Quarter.